



Review Article

Fibrates and Fibrate-induced Liver Injury in Primary Biliary Cholangitis



Alessandra Vanasco*  and Eric vanSonnenberg

College of Medicine, University of Arizona, Phoenix, USA

Received: March 29, 2023 | Revised: June 25, 2023 | Accepted: November 08, 2023 | Published online: December 25, 2023

Abstract

Primary biliary cholangitis (PBC) is a chronic, progressive autoimmune disease whose natural course leads to hepatic cirrhosis and failure, with an eventual need for liver transplantation. Treatment with ursodeoxycholic acid delays disease progression, but unfortunately, many patients do not respond to therapy. Obeticholic acid has shown promise as adjuvant therapy for incomplete responders but may exacerbate symptoms or even allow disease progression. Fibrates have been investigated for PBC and have shown therapeutic promise. However, they have been linked to rare but potentially severe cases of liver injury. In this review, we present an overview of PBC along with current therapies approved by the U.S. Food and Drug Administration. The literature was reviewed on PubMed from August 2022 to November 2023. We also discuss fibrate efficacy, overall safety, and the rare cases of liver injury. In conclusion, overall, fibrates are a relatively safe and effective adjuvant treatment for PBC.

Introduction

Primary biliary cholangitis (PBC), previously known as primary biliary cirrhosis,¹ is a cholestatic autoimmune disease that affects the liver. In PBC, T-cell activation against mitochondrial and nuclear antigens in biliary epithelial cells leads to the destruction of small- and medium-sized intralobular bile ducts. This results in progressive ductopenia, cholestasis, and fibrosis, with the potential to advance to cirrhosis and liver failure.^{2–4}

PBC is a rare disease, with an average reported incidence of 3.0 per 100,000 people/year and a prevalence of 21.1 per 100,000.⁵ It affects women more than men, at an estimated ratio of 6:1. The disease most often appears between the ages of 40 and 60 years.⁶ The geographic distribution of PBC varies considerably, with the highest concentrations in Europe and North America. It is uncertain how much the geographic disparity is due to true epidemiologic differences versus differences in disease recognition and reporting. Many studies demonstrate that the overall PBC prevalence has been increasing. Improved detection and survival are thought

to play a role in this increase, but there is a possibility that disease incidence is truly increasing.^{2,5}

PBC is most often diagnosed in asymptomatic patients by abnormalities detected on liver function tests obtained for unrelated reasons. To diagnose PBC, two out of three of the following are required: persistent elevation in alkaline phosphatase greater than 1.5 times the upper limit of normal, the presence of anti-mitochondrial antibodies in titers of at least 1:40, and liver biopsy that demonstrates a characteristic non-suppurative, asymmetric destruction of intralobular bile ducts.⁷

Patients who present with symptoms at the time of diagnosis usually complain of fatigue and pruritus. As the disease progresses, patients may develop further signs and symptoms of cholestatic liver disease that include jaundice, pale stools, dark urine, hepatomegaly, abdominal pain, xanthomas and xanthelasmas, malabsorption with fat-soluble vitamin deficiencies, osteoporosis, and the sequelae of cirrhosis.^{2–4} Even in the absence of cirrhosis, PBC-associated ductopenia can be severe enough to cause presinusoidal portal hypertension with associated esophageal varices, hepatic encephalopathy, and portopulmonary hypertension. The only effective treatment for these complications is a liver transplant.⁸

Keywords: Primary biliary cholangitis; Fenofibrate; Bezafibrate; Peroxisome proliferator-activated receptor; Liver injury.

Abbreviations: ACCORD, Action to Control Cardiovascular Risk in Diabetes; ALT, alanine transaminase; ALP, alkaline phosphatase; AST, aspartate transaminase; FDA, U.S. Food and Drug Administration; FIELD, Fenofibrate Intervention and Event Lowering in Diabetes; OCA, obeticholic acid; PBC, primary biliary cholangitis; PPAR, peroxisome proliferator-activated receptor; RXR, retinoic x receptor; UDCA, ursodeoxycholic acid.

***Correspondence to:** Alessandra Vanasco, College of Medicine, University of Arizona, 475 N 5th Street, Suite C523, Phoenix, Arizona 85004, USA. ORCID: <https://orcid.org/0000-0002-4655-9358>. Tel: 520-820-5032, E-mail: allyvanasco1@gmail.com

How to cite this article: Vanasco A, vanSonnenberg E. Fibrates and Fibrate-induced Liver Injury in Primary Biliary Cholangitis. *Gene Expr* 2023;22(4):321–328. doi: 10.14218/GE.2023.00015.

Current therapies

Although there is no cure for PBC, two medications are approved by the U.S. Food and Drug Administration (FDA) for treatment in the USA.

Ursodeoxycholic acid

Ursodeoxycholic acid (UDCA) was the first medication used to

treat PBC and remains first-line therapy currently. UDCA is a choleric, hydrophilic bile acid that occurs naturally in humans. Originally, it was used to dissolve cholesterol gallstones.^{4,9}

UDCA slows disease progression in PBC through several mechanisms. First, it stimulates hepatocyte and cholangiocyte secretion that reduces cholestasis and prevents cytotoxic buildup of bile acids. It inhibits intestinal reuptake of bile acids by increasing the hydrophilicity of the circulating bile acid pool that facilitates excretion, and decreases enterohepatic circulation. Finally, it demonstrates direct cytoprotective, anti-inflammatory, and immunomodulatory effects in cholangiocytes.^{10,11}

UDCA significantly improves biochemical markers of cholestasis, delays histologic disease progression, and prolongs liver transplant-free survival in patients with PBC.^{12–16} It is well-tolerated at the standard dose of 13–15 mg/kg/day. The most common side effect of UDCA is a change in bowel habits that rarely leads to treatment discontinuation.¹⁷

Response to UDCA treatment is variable, however. Several criteria are used to evaluate the adequacy of the response to treatment based on changes in biochemical markers at 1 year. Two of the most commonly used criteria are the UK-PBC score and the GLOBE score. Both scoring systems integrate levels of bilirubin, alkaline phosphatase (ALP), albumin, and platelets to predict the duration of transplant-free survival. The UK-PBC score additionally includes levels of aspartate transaminase (AST) and alanine transaminase (ALT), while the GLOBE score incorporates age at baseline.² Levels of ALP and total bilirubin levels are particularly effective surrogate markers for clinical outcomes of liver transplantation or death. The most favorable prognoses occur in patients who achieve total bilirubin levels below 0.6 times the upper limit of normal and ALP within normal limits.^{13,18}

Unfortunately, an estimated 40% of patients do not achieve a complete biochemical response with UDCA alone.^{18,19} Although incomplete UDCA responders still benefit from increased liver transplant-free survival compared to untreated patients with PBC, the magnitude of benefit is significantly less compared to that of complete responders.¹² There is evidence that starting UDCA early can prevent symptom development in asymptomatic patients, but it has not been reliably shown to relieve symptoms that are already present.^{17,20}

Obeticholic acid

Obeticholic acid (OCA) is a synthetic bile acid that through the activation of farnesoid X receptors in hepatocytes and enterocytes decreases bile synthesis and facilitates bile excretion.²¹ In the double-blind, placebo-controlled POISE trial, 217 patients with PBC who were refractory to or unable to tolerate UDCA were administered OCA up to 10 mg per day, and 93% of the participants continued to receive background treatment with UDCA. The primary endpoints of the trial were a reduction in ALP to less than 1.67 times the upper limit of normal, with a reduction of at least 15% from baseline, and a normalization of total bilirubin levels. After 1 year, 46–47% of patients who received OCA achieved the primary endpoints versus 10% in the placebo group.²² As a result of this study, the FDA granted accelerated approval of OCA for the treatment of PBC in 2016, with the stipulation that further post-marketing trials be conducted. Extensions of the POISE trial have demonstrated the lasting efficacy and safety of OCA at 3 years, as well as histologic evidence of disease stabilization or improvement.^{23,24} A separate study using OCA as monotherapy for PBC found significant and sustained reductions in ALP with an agreeable safety profile at 6 years.²⁵

OCA is not without drawbacks. The most common side effect is clinical worsening of pruritus in 68–70% of patients who received 10 mg daily; this was severe enough to result in treatment discontinuation in 10–15% of participants in two different studies.^{22,25}

The cost of OCA can be prohibitive as well. Even with an annual price reduction from over \$69,000 in 2017 to an estimated \$36,000 currently, the price would still need to decrease by about half to be cost-effective at a willingness-to-pay threshold of \$100,000 per quality-adjusted life year in PBC patients.^{26,27}

Although OCA is generally safe for patients with mild to moderate disease, there is evidence that those in the advanced stages of cirrhosis may experience clinical worsening and even death associated with the drug.²⁸ The FDA issued its first warning on the use of OCA in these patients in 2017, followed by a recommended dose reduction for cirrhotics in 2018. In 2021, a formal contraindication was issued against the use of OCA in patients with Child-Pugh class B or C cirrhosis, citing 25 reported cases of liver injury as a direct result of use between 2016 and 2021.²⁹

OCA has been shown to significantly improve the biochemical markers of PBC that can correlate with prolonged liver transplant-free survival, allowing nearly 50% of patients with incomplete biochemical response to UDCA alone to achieve a complete response. For those who cannot afford OCA, or cannot tolerate it, or are too advanced in their disease process to use it safely, alternative treatments are needed.

Emerging therapies

Additional treatments for PBC are much needed; therefore, several classes of medications are currently being investigated. Although PBC is an autoimmune disease, studies looking at the use of immunomodulatory agents largely have failed to show clinical efficacy.³⁰ Other agents, such as regulators of bile acid homeostasis, show potential but lack sufficient clinical data.³⁰ The most promising emerging treatment for PBC is fibrates. Fibrates are a class of medications that are known for their lipid-lowering effects. They are currently FDA-approved for the treatment of certain dyslipidemias.

Mechanism of action of fibrates

Fibrates activate peroxisome proliferator-activated receptors (PPARs), of which there are three major recognized isoforms: PPAR- α , PPAR- δ/β , and PPAR- γ . PPAR- α is expressed primarily in the liver, heart, kidneys, and intestines; PPAR- δ/β is expressed ubiquitously throughout the body; PPAR- γ is expressed primarily in adipose tissue.^{31,32} Once activated, PPAR receptors on the cell surface bind with retinoic X receptors, then translocate to the nucleus where they interact with PPAR response elements to alter gene expression.³³ Each fibrate has a unique affinity for the various PPAR subtypes. Of the two most commonly used fibrates for PBC, fenofibrate primarily acts on PPAR- α , while bezafibrate is a pan-PPAR agonist.³⁴

Most of what we know about the mechanism of fibrates relates to their effects on lipid metabolism. Fibrates have been shown to increase low-density lipoprotein catabolism and lipolysis of triglyceride-rich lipoproteins, reduce the available fatty acid substrate for use in triglyceride synthesis, and increase both high-density lipoprotein production and reverse cholesterol transport. The result of these various metabolic changes is an overall decrease in circulating triglyceride and cholesterol levels, a decrease in very low-density lipoproteins and an increase in high-density lipoproteins, all of which are salutary effects.^{35,36}

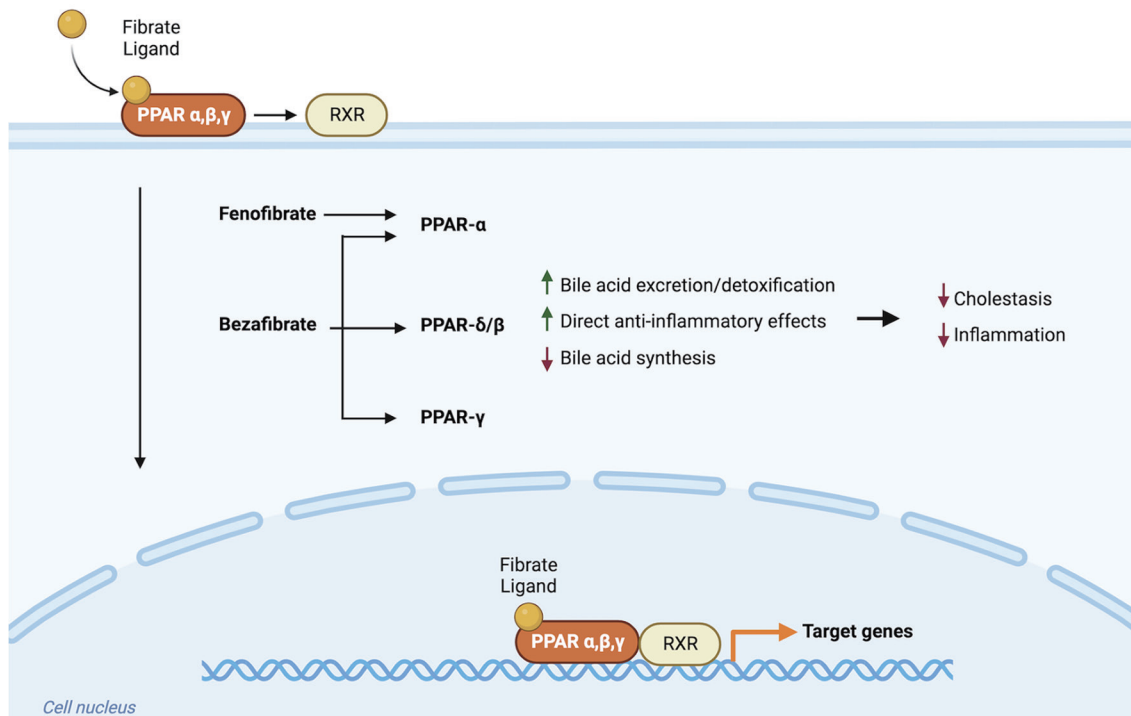


Fig. 1. Proposed mechanisms of action of fibrates in PBC. PBC, primary biliary cholangitis; PPAR, peroxisome proliferator-activated receptor; RXR, retinoic x receptor. (Created with BioRender.com).

The mechanism by which fibrates alter physiology in patients with PBC is incompletely understood. Studies on fenofibrate suggest that activation of PPAR- α causes simultaneous upregulation of genes that are involved in bile excretion and detoxification and downregulation of genes involved in bile acid synthesis. These effects are overall anti-cholestatic and anti-inflammatory. Bezafibrate, a pan-PPAR agonist, demonstrates the same effects, plus enhanced inhibition of bile acid synthesis through activation of the pregnane X receptor, as well as additional hypolipidemic, anti-inflammatory, and anti-fibrotic effects, thought to be mediated by PPAR- γ (Fig. 1).^{34,37-39}

Therapeutic potential of fibrates for PBC

There has been increasing interest in the therapeutic potential of fibrates in PBC over the last two decades. Studies conducted in the USA focus on fenofibrate, which is FDA-approved for treating dyslipidemia, whereas studies in Japan and Europe more often use bezafibrate. The most common dose for fenofibrate is 400 mg/day, and for bezafibrate, it is 160 mg/day.³⁰ A 2015 meta-analysis of 269 patients in nine trials found that adjuvant therapy with bezafibrate produced a significantly greater improvement in liver chemistries, including ALP and total bilirubin, compared to UDCA alone.⁴⁰ A separate 2015 meta-analysis found similar results in 102 incomplete UDCA responders in six trials using fenofibrate as adjuvant therapy; 69% of patients achieved normalization of ALP or a reduction of baseline levels by more than 40%, which qualifies as full biochemical response according to the Barcelona criteria.⁴¹

The largest and most impressive study of fibrates in PBC is the double-blind, placebo-controlled BEZURSO trial published in 2018. One hundred patients with incomplete UDCA response were randomized to receive adjuvant therapy with 400 mg of bezafibrate daily or placebo. They were followed for 24 months. The complete

biochemical response was defined as normal levels in total bilirubin, ALP, liver transaminases, albumin, and prothrombin index. At the end of the trial, 31% of patients in the bezafibrate group achieved full biochemical response, compared to 0% in the placebo group. Normalization of ALP occurred in 67% of the bezafibrate group vs. 2% in the placebo group.⁴²

In addition to biochemical improvement, there is evidence that fibrates may provide symptomatic benefit. Pruritus is one of the most common symptoms of PBC, and can appear at any point in the disease course. A study of 2,194 PBC patients found that nearly 74% had experienced pruritus.⁴³ Numerous trials investigating the biochemical effects of fibrates in PBC reported improvements in pruritus as a secondary endpoint.⁴⁴⁻⁴⁸ The randomized, placebo-controlled FITCH trial, published in 2021, analyzed the effects of bezafibrate on pruritus as a primary endpoint in 74 patients with cholestatic diseases, such as PBC and primary or secondary sclerosing cholangitis. After just 21 days, 45% of patients who received bezafibrate had a greater than 50% subjective decrease in pruritus, compared to 10% in the placebo group (Table 1).^{22,41,42,49-55}

The general safety of fibrates

Fibrates are well-tolerated in numerous studies, with a good overall safety profile. The majority of research has focused on the investigation of their anti-lipidemic effects and whether these might correlate to clinical cardioprotection. Two of the most noteworthy randomized controlled trials using fenofibrate include the Fenofibrate Intervention and Event Lowering in Diabetes (FIELD) study that followed 9,795 participants for 5 years and the Action to Control Cardiovascular Risk in Diabetes (ACCORD) study of 5,518 participants over 4.7 years. One of the largest randomized controlled trials involving bezafibrate is the Bezafibrate Infarction Prevention study, which followed 3,090 participants for 6.2 years.⁵⁶⁻⁵⁸

Table 1. Comparison of obeticholic acid, bezafibrate, and fenofibrate as adjunctive treatment for primary biliary cholangitis

Study	Year	Agent	Patients, n	Dose	Additional UDCA treatment	Full biochemical response	Effect on pruritus
Nevens <i>et al.</i> ²²	2016	Obeticholic acid	217	5–10 mg/day	Yes	46–47%	Increased in 56–68% of obeticholic acid group
Corpechot <i>et al.</i> ⁴²	2018	Bezafibrate	100	400 mg/day	Yes	31%	Decreased, unspecified amount
de Vries <i>et al.</i> ⁴⁹	2019	Bezafibrate	74	400 mg/day	Yes	Not assessed	Decreased in 41% of bezafibrate group
Dohmen <i>et al.</i> ⁵⁰	2004	Fenofibrate	9	100–150 mg/day	Yes	44%	Not assessed
Walker <i>et al.</i> ⁵¹	2009	Fenofibrate	16	134–200 mg/day	Yes	88%	Not assessed
Levy <i>et al.</i> ⁵²	2010	Fenofibrate	20	160 mg/day	Yes	55%	No significant effect
Han <i>et al.</i> ⁵³	2012	Fenofibrate	22	200 mg/day	Yes	68%	Not assessed
Hegade <i>et al.</i> ⁵⁴	2016	Fenofibrate	23	200 mg/day	Yes	53–80%	Not assessed
Li <i>et al.</i> ⁵⁵	2022	Fenofibrate	48	200 mg/day	Yes	21%	Not assessed

Adapted from Gigorian, Fenofibrate is effective adjunctive therapy in the treatment of primary biliary cirrhosis: A meta-analysis, Clinics and Research in Hepatology and Gastroenterology.⁴¹ PBC, primary biliary cholangitis; UDCA, ursodeoxycholic acid.

Gastrointestinal upset is the most common side effect of fibrates and occurs in up to 6.7% of fenofibrate users. Gastrointestinal upset causes approximately half of all adverse reactions; other side effects include rash, myalgias, and headaches.^{59,60} More rarely, fibrates have been associated with an increased risk of cholesterol gallstones, pancreatitis, venous thromboembolism, and pulmonary embolism, although all are uncommon.^{56–61} The most serious adverse events from fibrates are renal dysfunction, myopathy, and liver injury. A systematic review of 37 studies involving 1,107 patients with cholestatic liver disease (PBC and primary sclerosing cholangitis), treated with both UDCA and fibrates, found that the types of adverse events experienced with these medications were the same as those reported in patients without cholestatic disease, and occurred at similar rates.⁶²

A reversible increase in creatinine and a concomitant decrease in estimated glomerular filtration rate while on fibrate therapy has been widely reported. This is hypothesized to be due to PPAR-mediated inhibition of vasodilatory prostaglandin production, although there is evidence that PPAR activation may increase creatinine production directly.^{63,64} A recent meta-analysis examined 29 studies that administered fibrates to adults with chronic kidney disease or risk factors for chronic kidney disease. They found a mean increase in creatinine of 1.05 mg/dL and a mean decrease in the estimated glomerular filtration rate of –1.88 mL/min. These changes emerged early and remained stable with continued fibrate use, suggesting that prolonged therapy does not accentuate the effects. Cessation of fibrate therapy was sufficient to reverse these increases. The majority of patients had either normal kidney function or mild chronic kidney disease and were not at increased risk for renal failure with fibrate use. Albuminuria levels, an early and reliable marker of chronic kidney disease, actually decreased on average with fibrate use.⁶⁵

Fibrates cause myopathy in fewer than 1% of users. Fenofibrate causes myopathy without rhabdomyolysis in approximately 8.8 people per million prescriptions. It causes rhabdomyolysis in approximately 5.5 people per million prescriptions.⁶⁶ Rates of myopathy and rhabdomyolysis in large clinical trials such as the FIELD, ACCORD, and Bezafibrate Infarction Prevention studies were low, and there was no significant difference in incidence between the control and fibrate groups.^{57–59} Studies using rat models suggest that increased beta-oxidation leads to mitochondrial dysfunction, which may contribute to fibrate-induced myopathy, but the underlying mechanism remains unclear.⁶⁷ Certain fibrates are processed for elimination from the body by the same group of enzymes as most statins, and thus, co-administration can lead to higher plasma levels of both medications and increase the risk of myopathy. Fenofibrate, however, has not been shown to interfere with statin pharmacokinetics, and co-administration likely poses no risk.⁶⁸

Fibrate-induced liver injury

Fibrates cause elevations in liver transaminases in 3–7% of patients. In general, these elevations are asymptomatic, do not impair hepatic function, do not exceed 3x the upper limit of normal, and levels usually normalize with continuation of treatment.⁵⁹ Elevations above 3x the upper limit of normal occurred in less than 1% of fenofibrate and placebo users in the FIELD study and 1.9% of patients taking fenofibrate vs. 1.5% in the placebo group in the ACCORD study. Clinical hepatitis occurred in six patients per group in FIELD and in three patients in the fenofibrate group vs. 0 in the placebo group in ACCORD, which was not statistically significant.^{56,57} Studies in both rat models and humans suggest that these

increases in ALT and AST are due to PPAR- α -mediated upregulation in gene expression of these enzymes rather than reflective of hepatocyte injury.^{69–72} It is recommended that aminotransferase levels be monitored while on fibrate therapy and that therapy be discontinued if levels persist beyond 3x the upper limit of normal.

Rare but serious cases of fibrate-induced liver injury have been reported. The majority of data centers on fenofibrate and comes from individual case reports and reviews of national drug-induced liver injury registries.⁷³ Time from the start of therapy to the onset of apparent injury can vary from as short as several days to as long as several years. Most reported cases demonstrate a hepatocellular injury pattern, with predominant elevations in ALT, reflective of hepatocyte lysis^{74–83}; however, cases that demonstrate a cholestatic pattern with predominantly high ALP and a mixed pattern have also been reported.^{84–93} Clinically, patients may experience a range of symptoms and signs, including abdominal pain, jaundice, and fatigue, or can be asymptomatic. In cases when fibrates were used for at least 6 months before the hepatic injury was detected, biopsy tends to show marked fibrosis or even cirrhosis^{79–81}; those with onset of injury shorter than 6 months are more often characterized by cholestasis and ductopenia.^{91–93}

Cessation of the fibrate is sufficient to alleviate symptoms and rapidly normalize liver biochemistries in as quickly as several days to several months. A smaller subset of cases presented with a prolonged injury and the recovery time was closer to 1 year.^{79,82} In cases where a rechallenge was attempted, signs of injury recurred.^{76–78}

Variability in timing, biochemical pattern of injury, clinical presentation, and histological characteristics make it difficult to identify a mechanism underlying fibrate-induced liver injury. Additionally, much of the available data are affected by potentially confounding factors, such as medical comorbidities and polypharmacy. The current thought, however, is that fibrate-induced liver injury is likely immunologic. This theory is supported by the fact that several cases have presented with clinical and histologic features similar to autoimmune hepatitis and showed biochemical markers such as smooth muscle antibodies, antinuclear antibodies, and elevated immunoglobulins that improved with fibrate cessation.^{79–83,94,95}

Overall, the incidence of fibrate-induced liver injury is low; multicenter reviews and reviews of drug-induced liver injury registries in the USA and Spain found that fibrates are implicated in fewer than 1% of drug-induced liver injury cases.^{96–98} There have been no reports of acute liver failure attributed to fibrates and no cases of fibrate-induced liver injury that resulted in liver transplant.^{99,100} Of the case reports included in this paper, only one involved a patient with PBC.⁸⁶

Conclusions

Fibrates such as fenofibrate and bezafibrate improve biochemical markers of disease in patients with PBC when added to UDCA therapy, with additional evidence of symptomatic benefit. Fibrates are inexpensive, widely available, and generally safe. Although potentially severe, instances of fibrate-induced liver injury are exceedingly rare and, in most cases, quickly reversible without lasting impact with cessation of the drug. Careful monitoring of liver chemistries while on fibrate therapy is likely sufficient to detect signs of injury and prevent further damage.

Despite a strong safety profile and evidence of biochemical and symptomatic benefits, the FDA specifically contraindicates fibrates for cholestatic diseases such as PBC. Like all medicines,

fibrates certainly carry risk; however, when compared to patients without cholestatic disease, there has been no evidence to suggest that patients with PBC experience an increase in the frequency or severity of adverse effects from fibrates, including liver injury. In the absence of a cure and with so few treatment options available, efforts should be made to investigate further the mechanisms by which fibrates alter disease progression in PBC and how they can be maximized for safety and therapeutic efficacy.

The search for treatment options for PBC is ongoing. UDCA is an affordable, safe, and cost-effective first-line treatment that should be used for every individual diagnosed with PBC. In those patients who have a suboptimal response to UDCA alone, OCA may provide additional benefit, although potential side effects must be monitored closely, and the cost must be taken into consideration. The most promising emerging therapy for PBC is fibrates. Fibrates are a safe and effective adjuvant treatment for PBC in incomplete responders to UDCA. Those undergoing fibrate therapy should be followed closely for signs of liver injury.

Acknowledgments

There is nothing to declare.

Funding

There is nothing to declare.

Conflict of interest

The authors have no conflict of interests related to this publication.

Author contributions

Contributed to study concept and design, drafting of the manuscript, critical revision of the manuscript (AV and EvS); literature review (AV); supervision (EvS).

References

- [1] Beuers U, Gershwin ME, Gish RG, Invernizzi P, Jones DE, Lindor K, *et al.* Changing nomenclature for PBC: from ‘cirrhosis’ to ‘cholangitis’. *Am J Gastroenterol* 2015;110(11):1536–1538. doi:10.1038/ajg.2015.312, PMID:26416194.
- [2] Tanaka A. Current understanding of primary biliary cholangitis. *Clin Mol Hepatol* 2021;27(1):1–21. doi:10.3350/cmh.2020.0028, PMID:33264835.
- [3] Zhao Y, Wei S, Chen L, Zhou X, Ma X. Primary biliary cholangitis: molecular pathogenesis perspectives and therapeutic potential of natural products. *Front Immunol* 2023;14:1164202. doi:10.3389/fimmu.2023.1164202, PMID:37457696.
- [4] Galoosian A, Hanlon C, Zhang J, Holt EW, Yimam KK. Clinical Updates in Primary Biliary Cholangitis: Trends, Epidemiology, Diagnostics, and New Therapeutic Approaches. *J Clin Transl Hepatol* 2020;8(1):49–60. doi:10.14218/JCTH.2019.00049, PMID:32274345.
- [5] Colapietro F, Bertazzoni A, Lleo A. Contemporary epidemiology of primary biliary cholangitis. *Clin Liver Dis* 2022;26(4):555–570. doi:10.1016/j.cld.2022.06.001, PMID:36270716.
- [6] Trivella J, John BV, Levy C. Primary biliary cholangitis: Epidemiology, prognosis, and treatment. *Hepatol Commun* 2023;7(6):e0179. doi:10.1097/HC9.000000000000179, PMID:37267215.
- [7] European Association for the Study of the Liver. EASL clinical practice guidelines: management of cholestatic liver diseases. *J Hepatol* 2009;51(2):237–267. doi:10.1016/j.jhep.2009.04.009, PMID:19501929.

- [8] Bhan I, Schaefer EA, Bradley WR, Rodriguez-Lopez JM, Crowley JC, Hutchison B. Case 4-2023: A 56-year-old man with abnormal results on liver testing. *N Engl J Med* 2023;388(6):544–554. doi:10.1056/NEJMcp2201249, PMID:36780679.
- [9] Tustumi F, Pinheiro Filho JEL, Stolzemburg LCP, Serigiolle LC, Costa TN, Pajecki D, *et al.* Management of biliary stones in bariatric surgery. *Ther Adv Gastrointest Endosc* 2022;15:26317745221105087. doi:10.1177/26317745221105087, PMID:36388729.
- [10] Poupon R. Ursodeoxycholic acid and bile-acid mimetics as therapeutic agents for cholestatic liver diseases: an overview of their mechanisms of action. *Clin Res Hepatol Gastroenterol* 2012;36(Suppl 1):S3–12. doi:10.1016/S2210-7401(12)70015-3, PMID:23141891.
- [11] Cabrera D, Arab JP, Arrese M. UDCA, NorUDCA, and TUDCA in liver diseases: a review of their mechanisms of action and clinical applications. *Handb Exp Pharmacol* 2019;256:237–264. doi:10.1007/164_2019_241, PMID:31236688.
- [12] Harms MH, van Buuren HR, Corpechot C, Thorburn D, Janssen HLA, Lindor KD, *et al.* Ursodeoxycholic acid therapy and liver transplant-free survival in patients with primary biliary cholangitis. *J Hepatol* 2019;71(2):357–365. doi:10.1016/j.jhep.2019.04.001, PMID:30980847.
- [13] Lammers WJ, van Buuren HR, Hirschfield GM, Janssen HL, Invernizzi P, Mason AL, *et al.* Levels of alkaline phosphatase and bilirubin are surrogate end points of outcomes of patients with primary biliary cirrhosis: an international follow-up study. *Gastroenterology* 2014;147(6):1338–49.e5. doi:10.1053/j.gastro.2014.08.029, PMID:25160979.
- [14] Poupon RE, Lindor KD, Cauch-Dudek K, Dickson ER, Poupon R, Heathcote EJ. Combined analysis of randomized controlled trials of ursodeoxycholic acid in primary biliary cirrhosis. *Gastroenterology* 1997;113(3):884–890. doi:10.1016/S0016-5085(97)70183-5, PMID:9287980.
- [15] Lindor KD, Bowlus CL, Boyer J, Levy C, Mayo M. Primary biliary cholangitis: 2018 practice guidance from the American Association for the Study of Liver Diseases. *Hepatology* 2019;69(1):394–419. doi:10.1002/hep.30145, PMID:30070375.
- [16] Corpechot C, Carrat F, Bahr A, Chrétien Y, Poupon RE, Poupon R. The effect of ursodeoxycholic acid therapy on the natural course of primary biliary cirrhosis. *Gastroenterology* 2005;128(2):297–303. doi:10.1053/j.gastro.2004.11.009, PMID:15685541.
- [17] Lindor KD, Gershwin ME, Poupon R, Kaplan M, Bergasa NV, Heathcote EJ, American Association for Study of Liver Diseases. Primary biliary cirrhosis. *Hepatology* 2009;50(1):291–308. doi:10.1002/hep.22906, PMID:19554543.
- [18] Murillo Perez CF, Harms MH, Lindor KD, van Buuren HR, Hirschfield GM, Corpechot C, *et al.* Goals of treatment for improved survival in primary biliary cholangitis: treatment target should be bilirubin within the normal range and normalization of alkaline phosphatase. *Am J Gastroenterol* 2020;115(7):1066–1074. doi:10.14309/ajg.000000000000557, PMID:32618657.
- [19] Parés A, Caballería L, Rodés J. Excellent long-term survival in patients with primary biliary cirrhosis and biochemical response to ursodeoxycholic Acid. *Gastroenterology* 2006;130(3):715–720. doi:10.1053/j.gastro.2005.12.029, PMID:16530513.
- [20] Azemoto N, Abe M, Murata Y, Hiasa Y, Hamada M, Matsuura B, *et al.* Early biochemical response to ursodeoxycholic acid predicts symptom development in patients with asymptomatic primary biliary cirrhosis. *J Gastroenterol* 2009;44(6):630–634. doi:10.1007/s00535-009-0051-9, PMID:19370305.
- [21] Xiang D, Yang J, Liu L, Yu H, Gong X, Liu D. The regulation of tissue-specific farnesoid X receptor on genes and diseases involved in bile acid homeostasis. *Biomed Pharmacother* 2023;168:115606. doi:10.1016/j.biopha.2023.115606, PMID:37812893.
- [22] Nevens F, Andreone P, Mazzella G, Strasser SI, Bowlus C, Invernizzi P, *et al.* A placebo-controlled trial of obeticholic acid in primary biliary cholangitis. *N Engl J Med* 2016;375(7):631–643. doi:10.1056/NEJMoa1509840, PMID:27532829.
- [23] Trauner M, Nevens F, Shiffman ML, Drenth JPH, Bowlus CL, Vargas V, *et al.* Long-term efficacy and safety of obeticholic acid for patients with primary biliary cholangitis: 3-year results of an international open-label extension study. *Lancet Gastroenterol Hepatol* 2019;4(6):445–453. doi:10.1016/S2468-1253(19)30094-9, PMID:30922873.
- [24] Bowlus CL, Pockros PJ, Kremer AE, Parés A, Forman LM, Drenth JPH, *et al.* Long-term obeticholic acid therapy improves histological endpoints in patients with primary biliary cholangitis. *Clin Gastroenterol Hepatol* 2020;18(5):1170–1178.e6. doi:10.1016/j.cgh.2019.09.050, PMID:31606455.
- [25] Kowdley KV, Luketic V, Chapman R, Hirschfield GM, Poupon R, Schramm C, *et al.* A randomized trial of obeticholic acid monotherapy in patients with primary biliary cholangitis. *Hepatology* 2018;67(5):1890–1902. doi:10.1002/hep.29569, PMID:29023915.
- [26] Samur S, Klebanoff M, Banken R, Pratt DS, Chapman R, Ollendorf DA, *et al.* Long-term clinical impact and cost-effectiveness of obeticholic acid for the treatment of primary biliary cholangitis. *Hepatology* 2017;65(3):920–928. doi:10.1002/hep.28932, PMID:27906472.
- [27] Tran CP, Kim JJ, Feld JJ, Wong WW. Cost-effectiveness of obeticholic acid for the treatment of non-alcoholic steatohepatitis: An early economic evaluation. *Can Liver J* 2021;4(4):360–369. doi:10.3138/canlivj-2021-0011, PMID:35989894.
- [28] Eaton JE, Vuppalanchi R, Reddy R, Sathapathy S, Ali B, Kamath PS. Liver injury in patients with cholestatic liver disease treated with obeticholic acid. *Hepatology* 2020;71(4):1511–1514. doi:10.1002/hep.31017, PMID:31680292.
- [29] Sohal A, Kowdley KV. Primary biliary cholangitis: promising emerging innovative therapies and their impact on GLOBE scores. *Hepat Med* 2023;15:63–77. doi:10.2147/HMER.S361077, PMID:37312929.
- [30] Chascsa DMH, Lindor KD. Emerging therapies for PBC. *J Gastroenterol* 2020;55(3):261–272. doi:10.1007/s00535-020-01664-0, PMID:31970467.
- [31] Braissant O, Fougelle F, Scotto C, Dauça M, Wahli W. Differential expression of peroxisome proliferator-activated receptors (PPARs): tissue distribution of PPAR-alpha, -beta, and -gamma in the adult rat. *Endocrinology* 1996;137(1):354–366. doi:10.1210/endo.137.1.8536636, PMID:8536636.
- [32] Mirza AZ, Althagafi II, Shamshad H. Role of PPAR receptor in different diseases and their ligands: Physiological importance and clinical implications. *Eur J Med Chem* 2019;166:502–513. doi:10.1016/j.ejmech.2019.01.067, PMID:30739829.
- [33] Schoonjans K, Staels B, Auwerx J. Role of the peroxisome proliferator-activated receptor (PPAR) in mediating the effects of fibrates and fatty acids on gene expression. *J Lipid Res* 1996;37(5):907–925. PMID:8725145.
- [34] Ghonem NS, Assis DN, Boyer JL. Fibrates and cholestasis. *Hepatology* 2015;62(2):635–643. doi:10.1002/hep.27744, PMID:25678132.
- [35] Staels B, Dallongeville J, Auwerx J, Schoonjans K, Leitersdorf E, Fruchart JC. Mechanism of action of fibrates on lipid and lipoprotein metabolism. *Circulation* 1998;98(19):2088–2093. doi:10.1161/01.cir.98.19.2088, PMID:9808609.
- [36] Shepherd J. Mechanism of action of fibrates. *Postgrad Med J* 1993;69(Suppl 1):S34–41. PMID:8497455.
- [37] Honda A, Ikegami T, Nakamuta M, Miyazaki T, Iwamoto J, Hirayama T, *et al.* Anticholestatic effects of bezafibrate in patients with primary biliary cirrhosis treated with ursodeoxycholic acid. *Hepatology* 2013;57(5):1931–1941. doi:10.1002/hep.26018, PMID:22911624.
- [38] Mouton D, Butruille L, Staels B. PPAR control of metabolism and cardiovascular functions. *Nat Rev Cardiol* 2021;18(12):809–823. doi:10.1038/s41569-021-00569-6, PMID:34127848.
- [39] Corpechot C. The role of fibrates in primary biliary cholangitis. *Curr Hepatology Rep* 2019;18:107–114. doi:10.1007/s11901-019-00455-3.
- [40] Yin Q, Li J, Xia Y, Zhang R, Wang J, Lu W, *et al.* Systematic review and meta-analysis: bezafibrate in patients with primary biliary cirrhosis. *Drug Des Devel Ther* 2015;9:5407–5419. doi:10.2147/DDDT.S92041, PMID:26491252.
- [41] Grigoriou AV, Mardini HE, Corpechot C, Poupon R, Levy C. Fenofibrate is effective adjunctive therapy in the treatment of primary biliary cirrhosis: A meta-analysis. *Clin Res Hepatol Gastroenterol* 2015;39(3):296–306. doi:10.1016/j.clinre.2015.02.011, PMID:25882906.
- [42] Corpechot C, Chazouillères O, Rousseau A, Le Gruyer A, Habersetzer F, Mathurin P, *et al.* A placebo-controlled trial of bezafibrate in primary biliary cholangitis. *N Engl J Med* 2018;378(23):2171–2181. doi:10.1056/NEJMoa1714519, PMID:29874528.
- [43] Hegade VS, Mells GF, Fisher H, Kendrick S, DiBello J, Gilchrist K, *et*

- al. Pruritus is common and undertreated in patients with primary biliary cholangitis in the united kingdom. *Clin Gastroenterol Hepatol* 2019;17(7):1379–1387.e3. doi:10.1016/j.cgh.2018.12.007, PMID:30557739.
- [44] Reig A, Sesé P, Parés A. Effects of bezafibrate on outcome and pruritus in primary biliary cholangitis with suboptimal ursodeoxycholic acid response. *Am J Gastroenterol* 2018;113(1):49–55. doi:10.1038/ajg.2017.287, PMID:29016567.
- [45] Itakura J, Izumi N, Nishimura Y, Inoue K, Ueda K, Nakanishi H, *et al.* Prospective randomized crossover trial of combination therapy with bezafibrate and UDCA for primary biliary cirrhosis. *Hepatol Res* 2004;29(4):216–222. doi:10.1016/j.hepres.2004.04.001, PMID:15288014.
- [46] Lens S, Leoz M, Nazal L, Bruguera M, Parés A. Bezafibrate normalizes alkaline phosphatase in primary biliary cirrhosis patients with incomplete response to ursodeoxycholic acid. *Liver Int* 2014;34(2):197–203. doi:10.1111/liv.12290, PMID:23998489.
- [47] Takeuchi Y, Ikeda F, Fujioka S, Takaki T, Osawa T, Yasunaka T, *et al.* Additive improvement induced by bezafibrate in patients with primary biliary cirrhosis showing refractory response to ursodeoxycholic acid. *J Gastroenterol Hepatol* 2011;26(9):1395–1401. doi:10.1111/j.1440-1746.2011.06737.x, PMID:21443659.
- [48] Kanda T, Yokosuka O, Imazeki F, Saisho H. Bezafibrate treatment: a new medical approach for PBC patients? *J Gastroenterol* 2003;38(6):573–578. doi:10.1007/s00535-002-1102-7, PMID:12825134.
- [49] de Vries E, Bolier R, Goet J, Parés A, Verbeek J, de Vree M, *et al.* Fibrates for Itch (FITCH) in Fibrosing Cholangiopathies: A Double-Blind, Randomized, Placebo-Controlled Trial. *Gastroenterology* 2021;160(3):734–743.e6. doi:10.1053/j.gastro.2020.10.001, PMID:33031833.
- [50] Dohmen K, Mizuta T, Nakamuta M, Shimohashi N, Ishibashi H, Yamamoto K. Fenofibrate for patients with asymptomatic primary biliary cirrhosis. *World J Gastroenterol* 2004;10(6):894–898. doi:10.3748/wjg.v10.i6.894, PMID:15040040.
- [51] Walker LJ, Newton J, Jones DE, Bassendine MF. Comment on biochemical response to ursodeoxycholic acid and long-term prognosis in primary biliary cirrhosis. *Hepatology* 2008;49(1):337–338. doi:10.1002/hep.22670, PMID:19035342.
- [52] Levy C, Peter JA, Nelson DR, Keach J, Petz J, Cabrera R, *et al.* Pilot study: fenofibrate for patients with primary biliary cirrhosis and an incomplete response to ursodeoxycholic acid. *Aliment Pharmacol Ther* 2011;33(2):235–242. doi:10.1111/j.1365-2036.2010.04512.x, PMID:21083674.
- [53] Han XF, Wang QX, Liu Y, You ZR, Bian ZL, Qiu DK, *et al.* Efficacy of fenofibrate in Chinese patients with primary biliary cirrhosis partially responding to ursodeoxycholic acid therapy. *J Dig Dis* 2012;13(4):219–224. doi:10.1111/j.1751-2980.2012.00574.x, PMID:22435507.
- [54] Hegade VS, Khanna A, Walker LJ, Wong LL, Dyson JK, Jones DEJ. Long-Term Fenofibrate Treatment in Primary Biliary Cholangitis Improves Biochemistry but Not the UK-PBC Risk Score. *Dig Dis Sci* 2016;61(10):3037–3044. doi:10.1007/s10620-016-4250-y, PMID:27435324.
- [55] Li C, Zheng K, Chen Y, He C, Liu S, Yang Y, *et al.* A randomized, controlled trial on fenofibrate in primary biliary cholangitis patients with incomplete response to ursodeoxycholic acid. *Ther Adv Chronic Dis* 2022;13:20406223221114198. doi:10.1177/20406223221114198, PMID:35924008.
- [56] Keech A, Simes RJ, Barter P, Best J, Scott R, Taskinen MR, *et al.* Effects of long-term fenofibrate therapy on cardiovascular events in 9795 people with type 2 diabetes mellitus (the FIELD study): randomised controlled trial. *Lancet* 2005;366(9500):1849–1861. doi:10.1016/S0140-6736(05)67667-2, PMID:16310551.
- [57] ACCORD Study Group, Ginsberg HN, Elam MB, Lovato LC, Crouse JR 3rd, Leiter LA, *et al.* Effects of combination lipid therapy in type 2 diabetes mellitus. *N Engl J Med* 2010;362(17):1563–1574. doi:10.1056/NEJMoa1001282, PMID:20228404.
- [58] Bezafibrate Infarction Prevention (BIP) study. Secondary prevention by raising HDL cholesterol and reducing triglycerides in patients with coronary artery disease. *Circulation* 2000;102(1):21–27. doi:10.1161/01.cir.102.1.21, PMID:10880410.
- [59] Roberts WC. Safety of fenofibrate—US and worldwide experience. *Cardiology* 1989;76(3):169–179. doi:10.1159/000174488, PMID:2673510.
- [60] Tsui L, Chen L, Ye P, Xu S, Wu SJ, Chen SC, *et al.* Adverse drug reactions of non-statin antihyperlipidaemic drugs in China from 1989 to 2019: a national database analysis. *BMJ Open* 2023;13(5):e068915. doi:10.1136/bmjopen-2022-068915, PMID:37253501.
- [61] Knopp RH. Drug treatment of lipid disorders. *N Engl J Med* 1999;341(7):498–511. doi:10.1056/NEJM199908123410707, PMID:10441607.
- [62] Carrion AF, Lindor KD, Levy C. Safety of fibrates in cholestatic liver diseases. *Liver Int* 2021;41(6):1335–1343. doi:10.1111/liv.14871, PMID:33751787.
- [63] Tsimihodimos V, Miltiadous G, Bairaktari E, Elisaf M. Possible mechanisms of the fibrate-induced increase in serum creatinine. *Clin Nephrol* 2002;57(5):407–408. PMID:12036205.
- [64] Hottelart C, El Esper N, Rose F, Achard JM, Fournier A. Fenofibrate increases creatininemia by increasing metabolic production of creatinine. *Nephron* 2002;92(3):536–541. doi:10.1159/000064083, PMID:12372935.
- [65] Hadjivasilis A, Kouis P, Kousios A, Panayiotou A. The effect of fibrates on kidney function and chronic kidney disease progression: a systematic review and meta-analysis of randomised studies. *J Clin Med* 2022;11(3):768. doi:10.3390/jcm11030768, PMID:35160220.
- [66] Alsheikh-Ali AA, Kuvlin JT, Karas RH. Risk of adverse events with fibrates. *Am J Cardiol* 2004;94(7):935–938. doi:10.1016/j.amjcard.2004.06.033, PMID:15464682.
- [67] Pettersen JC, Pruimboom-Brees I, Francone OL, Amacher DE, Boldt SE, Kerlin RL, *et al.* The PPAR α agonists fenofibrate and CP-778875 cause increased β -oxidation, leading to oxidative injury in skeletal and cardiac muscle in the rat. *Toxicol Pathol* 2012;40(3):435–447. doi:10.1177/0192623311431945, PMID:22301950.
- [68] Jacobson TA, Zimmerman FH. Fibrates in combination with statins in the management of dyslipidemia. *J Clin Hypertens (Greenwich)* 2006;8(1):35–41. doi:10.1111/j.1524-6175.2005.05278.x, PMID:16407687.
- [69] Tomkiewicz C, Muzeau F, Edgar AD, Barouki R, Aggerbeck M. Opposite regulation of the rat and human cytosolic aspartate aminotransferase genes by fibrates. *Biochem Pharmacol* 2004;67(2):213–225. doi:10.1016/j.bcp.2003.07.018, PMID:14698034.
- [70] Thulin P, Rafter I, Stockling K, Tomkiewicz C, Norjavaara E, Aggerbeck M, *et al.* PPAR α regulates the hepatotoxic biomarker alanine aminotransferase (ALT1) gene expression in human hepatocytes. *Toxicol Appl Pharmacol* 2008;231(1):1–9. doi:10.1016/j.taap.2008.03.007, PMID:18455211.
- [71] Edgar AD, Tomkiewicz C, Costet P, Legendre C, Aggerbeck M, Bouguet J, *et al.* Fenofibrate modifies transaminase gene expression via a peroxisome proliferator activated receptor α -dependent pathway. *Toxicol Lett* 1998;98(1-2):13–23. doi:10.1016/s0378-4274(98)00042-3, PMID:9776557.
- [72] Kobayashi A, Suzuki Y, Kuno H, Sugai S, Sakakibara H, Shimoi K. Effects of fenofibrate on plasma and hepatic transaminase activities and hepatic transaminase gene expression in rats. *J Toxicol Sci* 2009;34(4):377–387. doi:10.2131/jts.34.377, PMID:19652460.
- [73] LiverTox: Clinical and Research Information on Drug-Induced Liver Injury. Bethesda (MD): National Institute of Diabetes and Digestive and Kidney Diseases; 2017. PMID:31643919.
- [74] Ma S, Liu S, Wang Q, Chen L, Yang P, Sun H. Fenofibrate-induced hepatotoxicity: A case with a special feature that is different from those in the LiverTox database. *J Clin Pharm Ther* 2020;45(1):204–207. doi:10.1111/jcpt.13042, PMID:31518450.
- [75] Aron E, Metman EH, Bougnoux P. Hepatitis due to procetofene? 1 case. *Nouv Presse Med* 1979;8(10):783. PMID:461126.
- [76] Vachon JM. Hepatitis caused by procetofen. *Nouv Presse Med* 1980;9(37):2740. PMID:6107896.
- [77] Migneco G, Mascarella A, La Ferla A, Attianese R. Clotofibrate hepatitis. A case report. *Minerva Med* 1986;77(19):799–800. PMID:3714094.
- [78] Lelouch S, Pelletier G, Sinico M, Ducreux M, Etienne JP. Fenofibrate-induced acute hepatitis with pseudo-cholangitis. *Gastroenterol Clin Biol* 1992;16(6-7):597–599. PMID:1526421.
- [79] Chatrenet P, Regimbeau C, Romain JP, Penot J, Bruandet P. Chronic active cirrhotogenic hepatitis induced by fenofibrate. *Gastroenterol Clin Biol* 1993;17(8-9):612–613. PMID:8253329.
- [80] Bernard PH, Lamouliatte H, Le Bail B, Bioulac-Sage P, Quinton A, Bala-

- baud C. Chronic active hepatitis associated with antinuclear antibodies induced by fenofibrate. *Gastroenterol Clin Biol* 1994;18(11):1048–1049. PMID:7705574.
- [81] Punthakee Z, Scully LJ, Guindi MM, Ooi TC. Liver fibrosis attributed to lipid lowering medications: two cases. *J Intern Med* 2001;250(3):249–254. doi:10.1046/j.1365-2796.2001.00848.x, PMID:11555130.
- [82] Dumortier J, Slim R, Chevallier M, Boillot O, Thauinat JL, Vaillant E, *et al.* Acute severe fibrosing hepatitis associated with ciprofibrate treatment. *Gastroenterol Clin Biol* 1999;23(12):1399–1400. PMID:10642628.
- [83] Rouhier ML, Rifflet H, Rifflet I, Oberti F, Vuillemin E, Chevailler A, *et al.* Painful acute liver involvement related to ingestion of fenofibrate. *Gastroenterol Clin Biol* 1996;20(12):1137–1138. PMID:9033862.
- [84] Fartoux-Heymann L, Narcy-Lambare B, Labayle D, Fischer D. Acute hepatitis and drug dermatitis due to fenofibrate (Secalip). *Ann Med Interne (Paris)* 2001;152(5):353–354. PMID:11593148.
- [85] Pichon N, Vincensini JF, Rozière A, Labrousse F, Sautereau D, Pillegand B. Acute cytolytic and cholestatic hepatitis induced by fenofibrate. *Gastroenterol Clin Biol* 2003;27(10):947–949. PMID:14631314.
- [86] Dohmen K, Wen CY, Nagaoka S, Yano K, Abiru S, Ueki T, *et al.* Fenofibrate-induced liver injury. *World J Gastroenterol* 2005;11(48):7702–7703. doi:10.3748/wjg.v11.i48.7702, PMID:16437706.
- [87] Tudesq N, Bentournes M. Hepatitis induced by fibrates. *Ann Biol Clin (Paris)* 2006;64(5):515–516. PMID:17124754.
- [88] Hajdu D, Aiglová K, Vinklerová I, Urbánek K. Acute cholestatic hepatitis induced by fenofibrate. *J Clin Pharm Ther* 2009;34(5):599–602. doi:10.1111/j.1365-2710.2009.01029.x, PMID:19744016.
- [89] Massen H, Furet Y. Hepatitis caused by fenofibrate. *Cah Anesthesiol* 1986;34(3):249–250. PMID:3742311.
- [90] Rigal J, Furet Y, Autret E, Breteau M. [Severe mixed hepatitis caused by fenofibrate? A review of the literature apropos of a case. *Rev Med Interne* 1989;10(1):65–67. doi:10.1016/s0248-8663(89)80119-5, PMID:2655052.
- [91] Ho CY, Kuo TH, Chen TS, Tsay SH, Chang FY, Lee SD. Fenofibrate-induced acute cholestatic hepatitis. *J Chin Med Assoc* 2004;67(5):245–247. PMID:15357112.
- [92] Lucena MI, Andrade RJ, Vicioso L, González FJ, Pachkoria K, García-Muñoz B. Prolonged cholestasis after raloxifene and fenofibrate interaction: A case report. *World J Gastroenterol* 2006;12(32):5244–5246. doi:10.3748/wjg.v12.i32.5244, PMID:16937543.
- [93] Lepicard A, Mallat A, Zafrani ES, Dhumeaux D. Chronic lesion of the interlobular bile ducts induced by fenofibrate. *Gastroenterol Clin Biol* 1994;18(11):1033–1035. PMID:7705563.
- [94] Ganne-Carrié N, de Leusse A, Guettier C, Castera L, Levecq H, Bertrand HJ, *et al.* Autoimmune hepatitis induced by fibrates. *Gastroenterol Clin Biol* 1998;22(5):525–529. PMID:9762291.
- [95] Homberg JC, Abuaf N, Helmy-Khalil S, Biour M, Poupon R, Islam S, *et al.* Drug-induced hepatitis associated with anticytoplasmic organelle autoantibodies. *Hepatology* 1985;5(5):722–727. doi:10.1002/hep.1840050504, PMID:4029887.
- [96] Andrade RJ, Lucena MI, Fernández MC, Pelaez G, Pachkoria K, García-Ruiz E, *et al.* Drug-induced liver injury: an analysis of 461 incidences submitted to the Spanish registry over a 10-year period. *Gastroenterology* 2005;129(2):512–521. doi:10.1016/j.gastro.2005.05.006, PMID:16083708.
- [97] Chalasani N, Fontana RJ, Bonkovsky HL, Watkins PB, Davern T, Serrano J, *et al.* Causes, clinical features, and outcomes from a prospective study of drug-induced liver injury in the United States. *Gastroenterology* 2008;135(6):1924–1934. doi:10.1053/j.gastro.2008.09.011, PMID:18955056.
- [98] Chalasani N, Bonkovsky HL, Fontana R, Lee W, Stolz A, Talwalkar J, *et al.* Features and Outcomes of 899 Patients With Drug-Induced Liver Injury: The DILIN Prospective Study. *Gastroenterology* 2015;148(7):1340–52.e7. doi:10.1053/j.gastro.2015.03.006, PMID:25754159.
- [99] Reuben A, Koch DG, Lee WM, Acute Liver Failure Study Group. Drug-induced acute liver failure: results of a U.S. multicenter, prospective study. *Hepatology* 2010;52(6):2065–2076. doi:10.1002/hep.23937, PMID:20949552.
- [100] Russo MW, Galanko JA, Shrestha R, Fried MW, Watkins P. Liver transplantation for acute liver failure from drug induced liver injury in the United States. *Liver Transpl* 2004;10(8):1018–1023. doi:10.1002/lt.20204, PMID:15390328.